

# Simultaneous Contour Augmentation to Immediate Implants with OSSIX® Plus

## A Case Study by Alberto Monje, DDS, MS, PhD

At Dentsply Sirona Regenerative Solutions, we strive to provide you with the latest advancements and trends in guided bone regeneration and guided tissue regeneration (GBR/GTR). Learn from clinical case studies tailored for dental professionals like you and elevate your practice .

### Background

Patient under supportive periodontal therapy presenting with fractures of the two lower canines during her regular recall appointment. She is an 80-year-old female who is otherwise in good health.

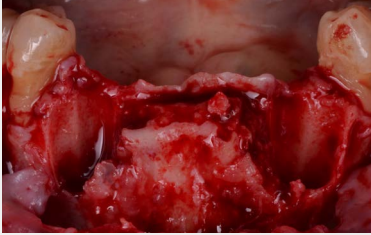### Case Description

In order to minimize the invasiveness of the extraction process and to provide immediate results, implants were placed immediately after extraction slightly deeper than the base of the bone, anticipating dimensional changes that may be caused by large bone defects resulting from ankylosis. A guided bone regeneration procedure was conducted using autogenous bone from the adjacent area, xenograft and OSSIX® Plus. In this approach, the membrane is key as it promotes early bone formation and due to its long-term dimensional stability, a flap is not strictly required for tension-free closure. There is the possibility of secondary intention healing to form spontaneously keratinized mucosa on the crestal aspect.

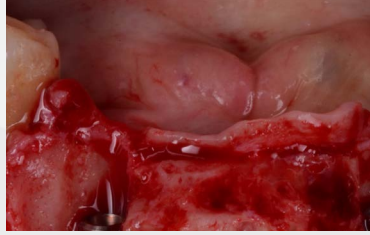Re-entry at four-month revealed abundant bone formation, requiring ostectomy to access the implants and place the healing abutments.

The clinical evaluation conducted at the two-year follow-up revealed that the patient was healthy and had adequate access to oral hygiene measures for self-care. Additionally, radiographic assessment revealed marginal stability at the bone level.

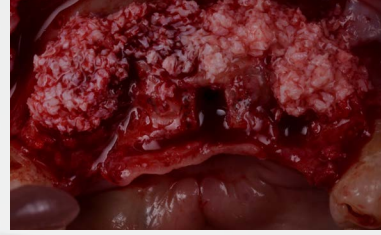## Surgery



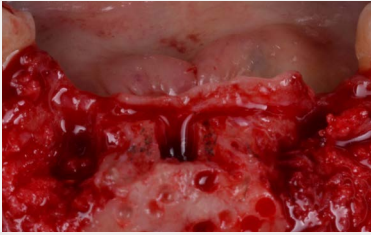
Extraction-related large bone defects



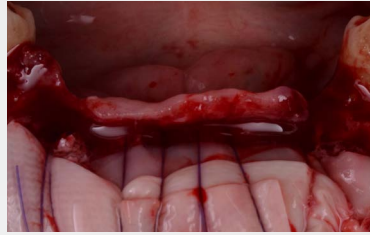Hybrid-design implants with sufficient primary stability



A xenograft was used to gain volume

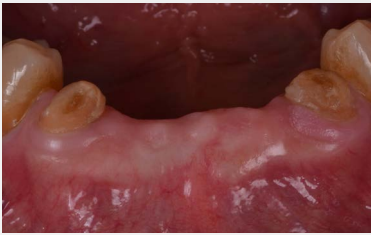

Autogenous bone was placed in proximity to the dental implant surface



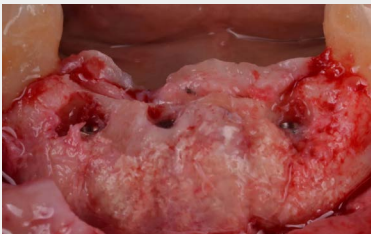The OSSIX® Plus was stabilized by suturing subperiosteally

## Pre-Op

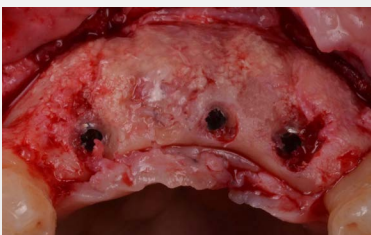

The baseline case scenario

## Post-Op After 4 Months

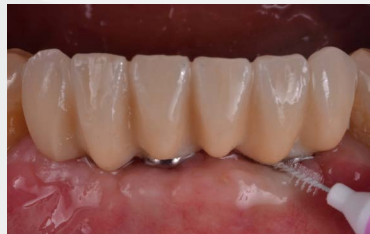

Frontal view of re-entry at four-month follow-up



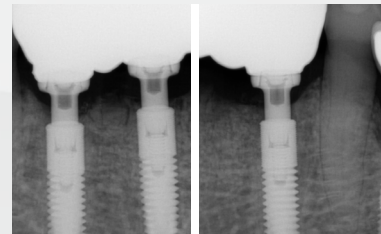
Occlusal view of re-entry at four-month follow-up

## Follow Up After 2 Years



Clinical evaluation at two-year follow-up

## Scans



Radiographic evaluation demonstrated marginal bone level stability

## OSSIX® Plus - Barrier Redefined



OSSIX® Plus is a resilient resorbable collagen barrier membrane that maintains barrier functionality for 4-6 months. It is resistant to degradation when exposed for 3-5 weeks and has excellent handling properties, adapting and conforming to defects, and adhering well to tissue. OSSIX® Plus maintains a high biocompatibility and has been observed to undergo ossification<sup>1-5</sup>.



### About the Clinician, Dr. Alberto Monje, DDS, MS, PhD

Dr. Alberto Monje obtained his certificate and Masters in Periodontology from the University of Michigan, Department of Periodontics and Oral Medicine. He is certified by the American Board of Periodontics.

He was the recipient of the ITI Scholarship for 2016-2017 at the University of Bern mentored by Prof. Daniel Buser.

Dr. Monje is a PhD in the field of Alveolar Bone Architecture granted by the University of Granada in Spain. He maintains a private practice exclusively in Periodontics and Implant Dentistry.

He is an adjunct professor at the Department of Periodontics of the Universitat Internacional de Catalunya in Barcelona and at the Department of Periodontics and Oral Medicine at the University of Michigan, Ann Arbor, Michigan, USA.

## Reference

1. Zubery et al. (2007). Ossification of a novel cross-linked porcine collagen barrier in guided bone regeneration in dogs. J Periodontol 78:112- 121. • Zubery et al. (2008). Ossification of a collagen membrane cross-linked by sugar: a human case series. J Periodontol. 79:101-1107.
2. Tal H, Kozlovsky A, Artzi Z, Nemcovsky CE, Moses O. (2008) Long-term biodegradation of cross-linked and non-cross-linked collagen barriers in human guided bone regeneration. Clin Oral Implants Res. 19(3):295-30.
3. Capri G, Smukler H, Landi L. (2012) A less invasive approach to mandibular horizontal ridge augmentation using autogenous bone: A human histological case series. The Journal of Implants and Advanced Clinical Dentistry 4:27-36.
4. Artzi Z, Weinreb M, Carmeli G, Lev-Dor R, Dard M, Nemcovsky CE. (2008) Histomorphometric assessment of bone formation in sinus augmentation utilizing a combination of autogenous and hydroxyapatite/biphasic tricalcium phosphate graft materials: at 6 and 9 months in humans. Clin. Oral Impl. Res. 19; 686–692.
5. Heather R. Hong et al. (2018) Ridge preservation procedures revisited: A randomized controlled trial to evaluate dimensional changes with two different surgical protocols, Journal of Periodontology, Volume 90, Issue4.

\* Dr. Monje receives financial support from Dentsply Sirona

Please read the [IFU](#) before use and for additional information on indications, contraindications, warnings, and precautions.

For more information on OSSIX® regenerative products and activities in your region:  
[regenerative.dentsplysirona.com](https://regenerative.dentsplysirona.com)

MKT-0003152 VER-01