

A Pericardium Membrane powered by
GLYMATRIX® Technology



Dr. Theofilos Koutouzis, DMD MS
Periodontist
Private clinic, Florida, US

Ridge Augmentation following implant removal due to peri-implant disease

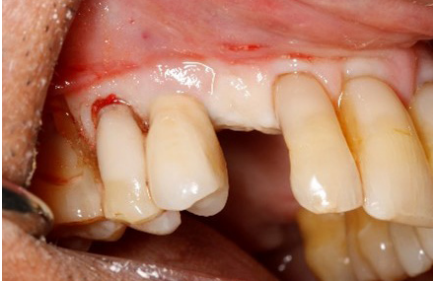A 70-year-old diabetic patient presented with peri-implantitis in the region of tooth #5, along with a reduced periodontium and horizontal and vertical deficiencies in tooth #6

Due to the hopeless prognosis of implant #5, the treatment plan involved its extraction and simultaneous augmentation of both the #5 and #6 sites to facilitate future implant placement. Clinical assessments revealed a significant 70% bone loss around implant #5 and a 3-4 mm vertical deficiency at the #6 site.

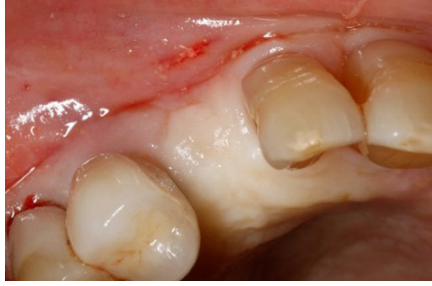Radiographic evaluation confirmed these findings. To support bone regeneration and enhance the surgical procedure, we utilized OSSIX Agile™ Membrane (20*30 mm), Particulate Allograft (1.0cc) for bone support, and Meisinger Tacks (3mm) in two units.

This case spotlights the successful management of peri-implantitis and the preparation of the surrounding area for subsequent implant placement in a diabetic patient.

Pre-Op



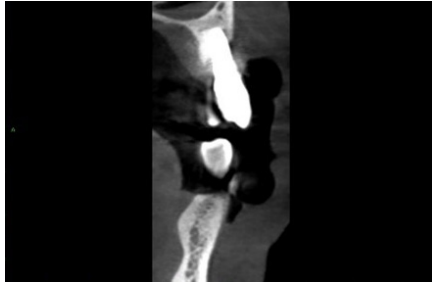
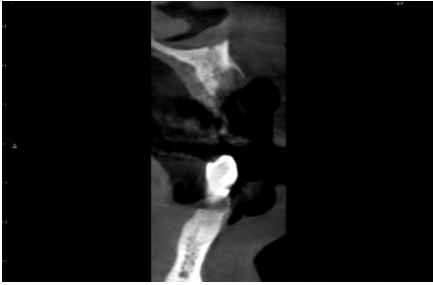
1. Facial view of an edentulous ridge and a failed implant



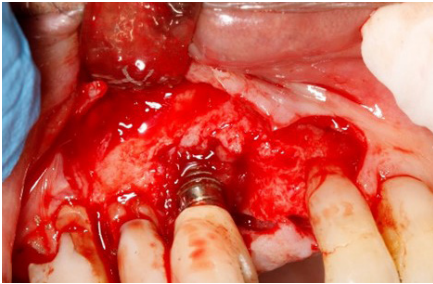
2. Occlusal view of an edentulous ridge and a failed implant

Pre-Op Scans

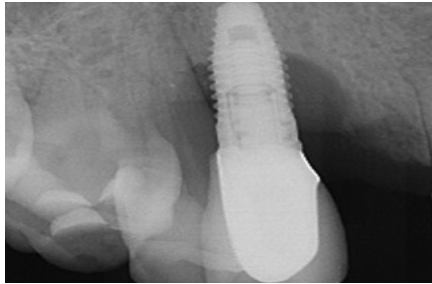
Scan of the edentulous area and the failing implant prior to ridge augmentation



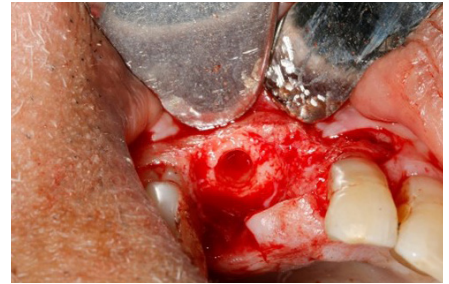
Surgery



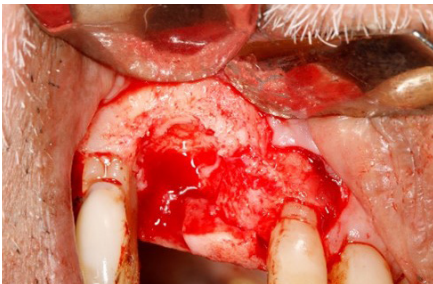
1. Facial view of an implant with severe bone loss and an atrophic ridge mesial to that.



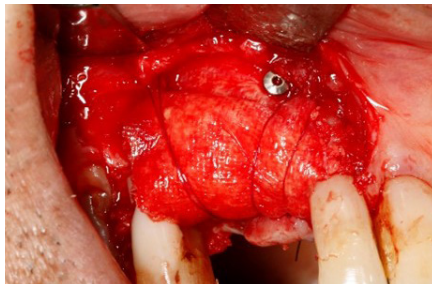
2. Periapical radiograph of an implant with severe bone loss



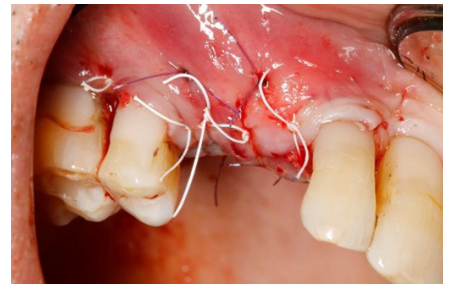3. Occlusal view, a vertical defect follows implant removal, with a mesial horizontal defect



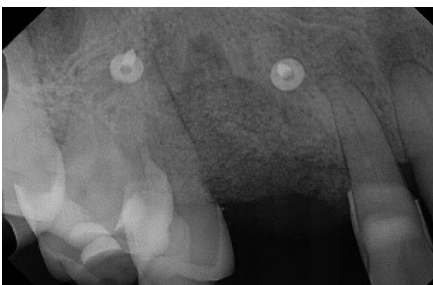
4. Facial view reveals a vertical defect after implant removal, along with a mesial horizontal defect



5. Facial View of the grafted defect and membrane stabilization with pins and sutures

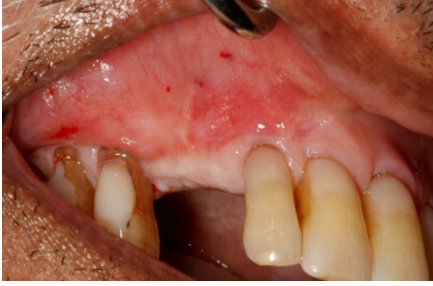

6. Facial view following suturing

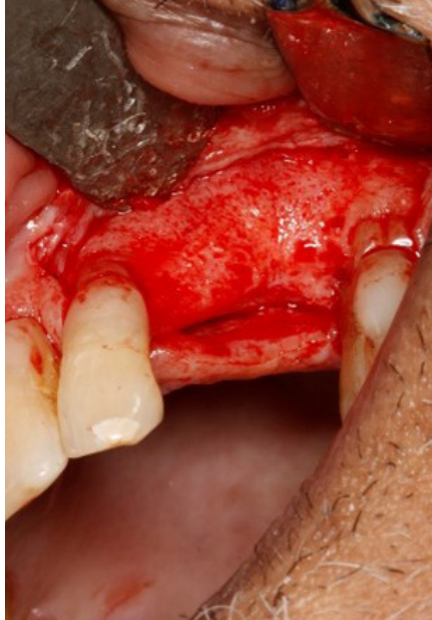

7. Periapical radiograph at the end of the surgery

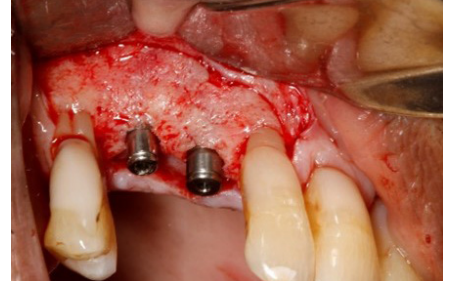
Re-entry after 4.5 Months



1. Facial view of the regenerated ridge, prior to flap elevation



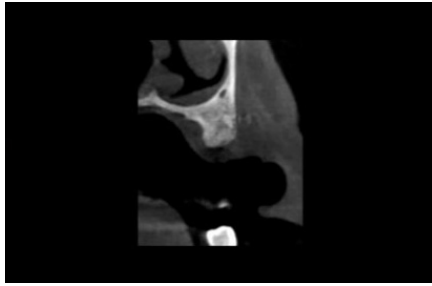
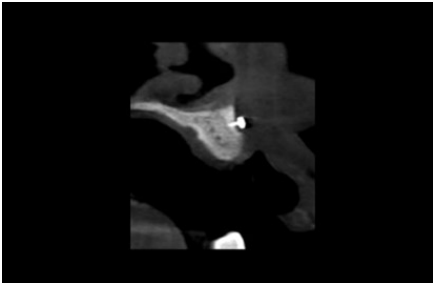
2. Facial view of the regenerated area



3. Facial view of implants placed at the regenerated defect

Post-Op Scans

6 months following ridge augmentation



For more information on OSSIX® regenerative products and activities on your region:

www.datumdental.com



This case report is published as an inspiration for you as a clinician / technician and not necessarily as a recommendation from Dentsply Sirona